

PERSONALIZED ADAPTIVE RADIATION THERAPY USING IMAGE GUIDED APPROACH IN PATIENTS WITH LUNG CANCER

D.Katsochi, C.Paraskevopoulou, S.Kosmidis, A.Fotopoulou, G.Kollias

Radiation Therapy Center of Diagnostic and Therapeutic Center of Athens, HYGEIA



INTRODUCTION / PURPOSE

In patients with advanced unresectable non small cell lung cancer local tumor control is the main goal. The introduction of image guided radiotherapy offers the opportunity to apply safely a supplementary dose to the macroscopic disease at the same time. This accelerated radiotherapy course, known as concomitant boost, has the advantage of increasing the total dose delivered without increasing the number of fractions. The registered result is an early tumor response without major side effects.

MATERIALS / METHODS

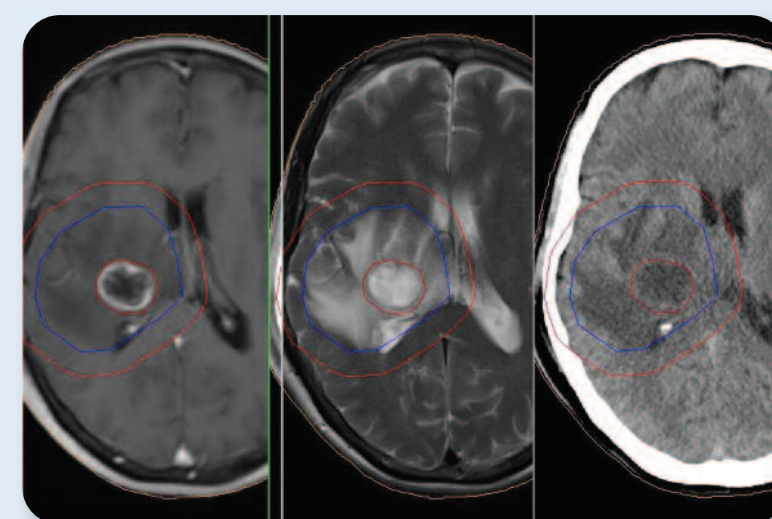
From May 2009 to May 2013, 73 patients with lung cancer were treated with concomitant boost technique. Patients were treated using the conformal or VMAT technique. Planning target volume (PTV) was treated daily with 1.8 Gy for 5 to 6 weeks to a total dose of 45-54Gy, while the dose to the Gross Tumor Volume (GTV) was boosted up to 55-65Gy depending on the anatomic region. Organs at risk were irradiated to safe limits. In 74% of the patients we readapted the treatment plan due to local tumor regression using image guidance data (CBCT). Patients received chemotherapy during radiation therapy.

RESULTS

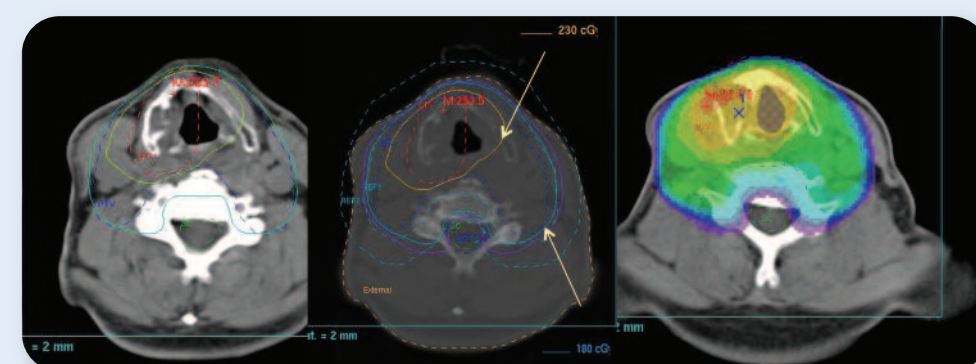
All patients completed the treatment plan with no major toxicity. Follow up was scheduled at the end of the treatment, three and nine months after. All patients achieved local tumor control, 78 patients with complete tumor response, 39 patients with partial response and 10 with stable disease.

CONCLUSIONS

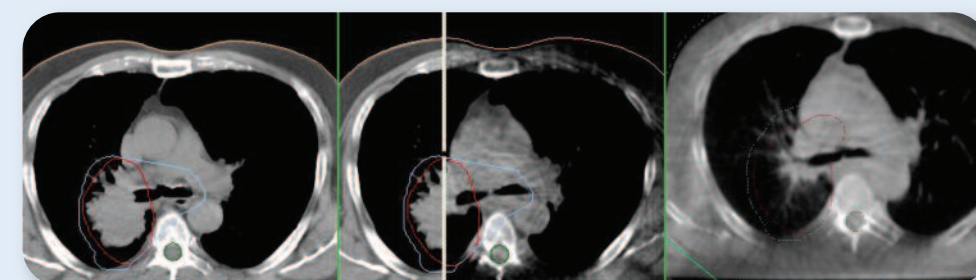
Image Guided Radiotherapy allowed a feasible, safe and effective treatment for patients with unresectable non small cell lung cancer using concomitant boost technique to macroscopic disease. Results are encouraging and promising regarding early locoregional disease control.



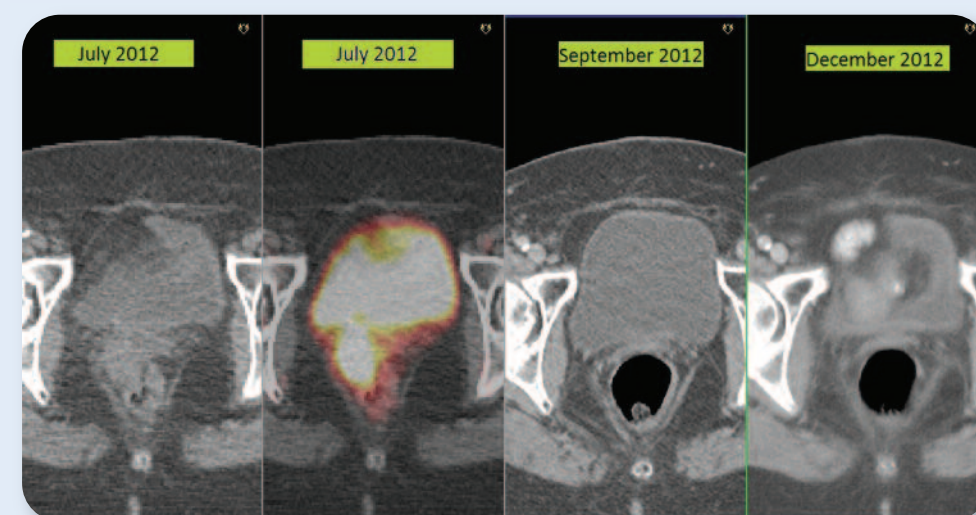
Brain tumor MRI and CT images fused. Delineation of GTV (tumor), CTV (edema), PTV planning tumor volume. Concomitant boost to GTV



Dose painting to the hypometabolic part of the laryngeal tumor



Lung cancer. Delineation of GTV (tumor) and PTV. Concomitant boost to GTV. Follow up CBCT shows tumor early response.



Follow up in patient with cervical cancer Complete response after radiation therapy with the technique concomitant boost